

# The use of aortic occlusion balloon catheter without fluoroscopy for life-threatening post-partum haemorrhage

E. SØVIK<sup>1</sup>, P. STOKKELAND<sup>2</sup>, B. S. STORM<sup>3</sup>, P. ÅSHEIM<sup>3</sup> and O. BOLÅS<sup>4</sup>

<sup>1</sup>Department of Radiology, St. Olavs University Hospital, Trondheim, Norway, <sup>2</sup>Department of Radiology, Stavanger University Hospital, Stavanger, Norway, <sup>3</sup>Department of Anesthesiology, St. Olavs University Hospital, Trondheim, Norway and <sup>4</sup>Department of Gynecology and Obstetrics, St. Olavs University Hospital, Trondheim, Norway

This article describes the use of a balloon catheter introduced via the femoral artery into the abdominal aorta without the use of fluoroscopy to stabilize six patients with life-threatening post-partum haemorrhage. The femoral artery was localized blindly or with the use of ultrasound. Immediate control of the bleeding was achieved in all patients, and the procedure was believed to be life saving for some patients. One patient with a narrow and fragile aorta had an aortic rupture necessitating surgical repair, which may have been caused by the balloon. In these six cases, the procedures were carried out by interventional radiologists.

However, this procedure can also be performed by anaesthesiologists or surgeons who are trained in vascular access techniques.

Accepted for publication 4 November 2011

© 2012 The Authors  
Acta Anaesthesiologica Scandinavica  
© 2012 The Acta Anaesthesiologica Scandinavica Foundation

## Case report

**S**EVERE post-partum haemorrhage (PPH) occurs in 1/1000 women giving birth.<sup>1</sup> This condition is often dramatic and may be life threatening.

Treatments with intravenous fluids, volume expanders and blood products and the use of inotropic agents have been the only options for anaesthesiologists and obstetricians in cases with heavy bleeding. For obstetricians, B-Lynch sutures and a hysterectomy may be the only solutions to halt bleeding, especially when the use of curettage, uterotonic drugs, manual compression and an intrauterine balloon has failed. Arterial embolization is also an option. However, this expertise is not always readily available.<sup>2</sup>

There have been several reports describing the use of aortic balloons to control bleeding in battle casualties and in patients with aortic aneurysms or aortic damage.<sup>3–6</sup> In recent years, there have also been reports on the use of aortic occlusion catheters to control exsanguination in patients with late surgical or obstetric bleeding in the abdomen or

pelvis.<sup>7–9</sup> A common technique in these reports is the use of fluoroscopy or computerized tomography (CT) in order to place the catheter in the correct position in the aorta. Recently, there was a report describing the use of intra-aortic balloon occlusion (IABO) without fluoroscopy to stop life-threatening bleeding in patients with pelvic fractures.<sup>10</sup>

In this report, we present six patients with severe PPH treated with IABO without the use of fluoroscopy or CT. All patients were treated by a team consisting of an interventional radiologist (IR), an anaesthesiologist and an obstetrician. All patients received misoprostol, oxytocin and a standard blood replacement treatment, including crystalloids, colloids, platelets, red blood cells (RBC) and inotropic drugs. All patients made uneventful recoveries.

## Cases

### Patient 1

Labour was induced during week 37 of gestation in a 26-year-old primigravida woman due to severe

pre-eclampsia. Due to PPH, atony of the uterus was suspected. A curettage (revision treatment) was performed. Nevertheless, major bleeding through the cervical channel [haemoglobin (Hb) fell to 5 g/dl] was observed despite an injection of carboprost directly into the myometrium.

The IR was called and inserted an aortic balloon under ultrasound (US) guidance. The blood pressure (BP) increased immediately, with systolic values rising from approximately 60 mmHg to 110 mmHg, and the bleeding stopped. The balloon was inflated for 40 min, which was only interrupted by two short deflations after 10 and 25 min. After 40 min, there was no bleeding when the balloon was deflated due to sufficient contraction of the uterus. Subsequently, the balloon was removed, but the introducer was left inside the femoral artery for 4 h before it was removed. Altogether, the patient was given 9 units of RBC, 8 units of concentrated platelets and 6 units of human plasma solution. The total blood loss was estimated to be 3500 ml.

#### *Patient 2*

A 38-year-old woman was admitted at term for her second childbirth. Soon after delivery, increasing vaginal bleeding was observed, and post-partum atony was suspected. Due to uncontrollable bleeding, she was admitted to the operation theatre with an Hb level of 4.7 g/dl. Gynaecological inspection revealed several vaginal tears and an atonic uterus. Carboprost was given intramyometrically.

An IABO catheter was inserted without the use of US. An initial increase in systolic BP from 40 mmHg to 80 mmHg was achieved after treatment with intravenous volume expanders. The systolic BP increased further from 80 mmHg to 130 mmHg as the balloon was inflated, and partial haemostasis simplified the suturing of the vaginal tears. After 30 min, the balloon was deflated, which was accompanied by a fall in systolic BP to 60 mmHg. Subsequently bleeding was attributed to be mainly caused by atony of the uterus. Afterwards, a hysterectomy was performed; however, vaginal bleeding was observed. Therefore, the patient was taken to the angiography laboratory for embolization, with the balloon still inflated. After deflation of the balloon, no bleeding was observed and embolization was not performed. The balloon was then removed, and the arterial introducer was left in place until the next day. The total estimated blood loss was 10 l.



Fig. 1. Picture of the NuMED PTX-S 25 × 30 mm balloon used in patient 3.

#### *Patient 3*

After delivery of a healthy baby, a 30-year-old primigravida woman developed a profound vaginal bleeding. The patient presented with pre-shock symptoms and was taken to the operating theatre. Under general anaesthesia, an IABO catheter was rapidly inserted under US guidance into the abdominal aorta. An immediate increase in BP from below 70 mmHg to over 90 mmHg was noted. The balloon was partly deflated after 1 min and retracted to the aortic bifurcation where it was reinflated and left for 10 min before the second deflation. No vaginal bleeding or cervical tears were seen, but placental material was evacuated by curettage. The balloon was inflated for a third time for 13 min before deflation. Meanwhile, carboprost was given intramyometrically. After these procedures, the uterus was well contracted, and the bleeding gradually stopped. The total blood loss was estimated to be 2300 ml. (Fig. 1)

The femoral introducer was left in place until the next day. (Fig. 2)

#### *Patient 4*

Planned labour was induced with misoprostol due to gestational impaired glucose tolerance in a 44-year-old woman at term.

After delivery, PPH was observed, with blood loss increasing after 1 h to 1700 ml as the patient developed atony of the uterus. Curettage was performed, and minimal residual placenta was removed. An intrauterine balloon and B-Lynch sutures were used without effect. A hysterectomy

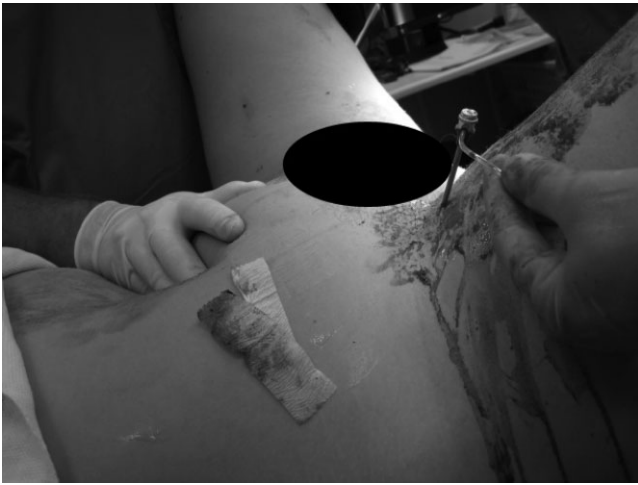

Fig. 2. Patient 3 with an 8 French introducer left in the common right femoral artery after removal of the aortic balloon. The introducer was removed the following day.

and US-guided insertion of an IABO catheter were performed simultaneously. The balloon was inflated, and the BP immediately rose from 70 mmHg to 110 mmHg, and haemostasis was achieved. The balloon was deflated after 15 min. Some bleeding was still observed in the operating field, but after a few additional minutes with the balloon reinflated, the balloon was removed without further bleeding. The estimated total blood loss was 9 l. The introducer was left in place. During the next day, the patient was stable but had minor ongoing bleeding that required transfusion. Embolization of the uterine artery was performed, which resulted in a permanent haemostasis.

#### Patient 5

A 30-year-old woman was admitted for her third childbirth. The patient had gestational diabetes during this third pregnancy. After delivery, the patient had a retained placenta, and manual extraction and revision were performed. The patient had ongoing bleeding due to atony despite intravenous medication and intramyometrial prostaglandin administration. She was given 21 units of RBC, 6 units of human plasma solution and 8 IU of platelets. An intrauterine balloon was unsuccessful, and Hg fell to 3.5 g/dl. An aortic balloon was inserted under US guidance, which caused the bleeding to stop immediately, with a rise in the systolic BP from 85 mmHg to 115 mmHg. A hysterectomy was performed without further complications. The introducer was removed the following day, and the

patient made an uneventful recovery. The total blood loss was estimated to be 7 l.

#### Patient 6

A 26-year-old woman collapsed during labour with a loss of consciousness and a fall in systolic BP initially to below 90 mmHg, which was followed by a drop in the heart rate of the baby. An acute Caesarean section was successfully performed. However, the mother's BP rapidly fell below 60 mmHg, which occurred simultaneously with a massive vaginal bleeding. The blood loss was estimated to be 3 l in 10 min. An aortic occlusion balloon was inserted with US guidance and was inflated with approximately 10 ml saline. An immediate increase in BP to above 90 mmHg was noted, but heavy vaginal bleeding was still reported. Doppler examination of the left femoral artery revealed both a venous pulse and a pulse in the femoral artery. A small hole in the balloon or an underinflated balloon was suspected; therefore, an additional 3–4 ml of saline was injected into the balloon. The bleeding gradually stopped, and the BP stabilized between 90 and 100 mmHg.

After 15 and 30 min, the balloon was slightly deflated, which resulted in an immediate fall in BP to below 60 mmHg. A hysterectomy was then performed, which was followed by a new dramatic fall in BP immediately after deflation of the balloon. Damage to the aorta was suspected, and the vascular surgeons were called. The balloon was rapidly changed, and the new balloon was inserted 40 cm from the insertion point in the right groin in order to stop the suspected bleeding. Again, the BP increased slowly to 85 mmHg as the patient was given massive transfusions. Surgical examination revealed a gracile infrarenal aorta that was found to have a diameter of only 1.2 cm, measured after suturing of the vessel wall and with the circulation restored in the vessel.

Total blood loss was estimated to be at least 15 l, and the patient was given 39 units of RBC, 27 units of human plasma solution, 36 IU of platelets and 3 doses of recombinant activated factor VII. She was reoperated 4 h later due to ongoing bleeding from the upper portion of the vagina. After 4 days in the intensive care unit, she made a full recovery. (Fig. 3)

## Methodology

In 2008, we assembled an 'aortic occlusion kit' that consisted of two NuMED PTX-S [NuMED Canada Inc., Cornwall, ON, Canada (25 × 30 mm)] paediatric

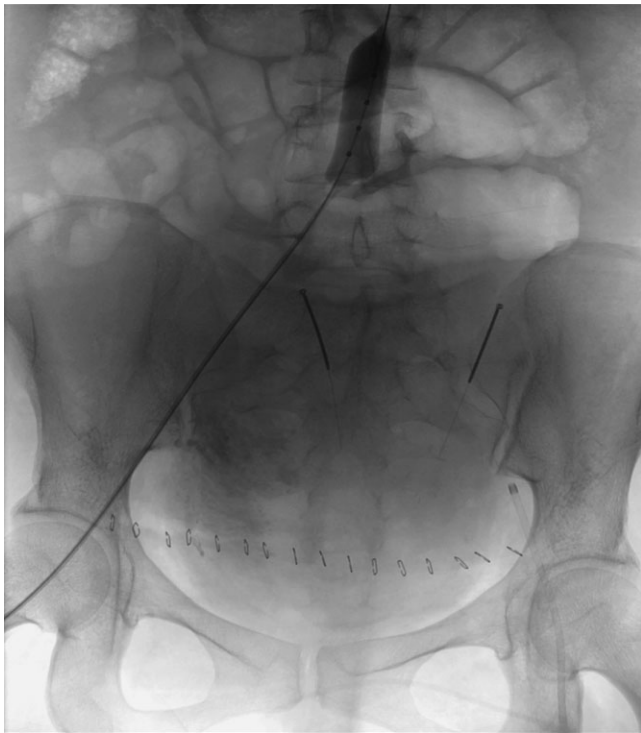


Fig. 3. X-ray picture from an embolization procedure of the uterine arteries after a Caesarean section. This patient is not referred to in this article; however, this image illustrates the position of an aortic occlusion balloon inflated in the distal abdominal aorta.

sizing balloons, two pairs of sterile gloves, two femoral insertion needles, two 8 French introducers, sterile dressings and two J-curved 150 cm 0.35 guidewires. This kit was placed near the operating room at the Department of Gynaecology and Obstetrics in the two hospitals. We also added the use of an aortic occlusion balloon to the procedure list for the obstetrician. The on-call IR was to be contacted with a response time less than 30 min in these situations.

All patients had weak or no palpable pulses in the right femoral artery due to hypotension. Under aseptic conditions, the needle was inserted under US guidance in five of the six patients. The IABO catheter was introduced through the right common femoral artery in all patients.

The J-curved guide wire was inserted smoothly at approximately 50 cm. If any resistance was felt, the wire was retracted and inserted a second time under US guidance to assure an intraluminal position. However, this was not a problem in any patients. An 8 French introducer was introduced through the femoral artery before the balloon was placed approximately 30 cm from the puncture site into the

abdominal aorta by the Seldinger technique. The balloon was inflated with isotonic saline until a slight resistance was felt, which was usually after the injection of approximately 10 ml. In three of the six cases, the balloon was deflated approximately 50% after a short time and then retracted until a slight resistance was felt. At this point, it was believed the balloon had entered the proximal part of the common iliac artery. The balloon was then reinflated until the bleeding stopped.

The occlusion balloon was inserted via the common femoral artery only by palpation of the femoral pulse in one case and with US guidance in five cases. After inserting the guidewire of approximately 50 cm, the wire was believed to be situated in the lower descending thoracic aorta. Using an 8 French introducer, a NuMED PTX-S (NuMED Canada Inc., Cornwall, ON, Canada) 25–30 mm balloon catheter was inserted approximately 30 cm into the abdominal aorta.

## Discussion

Clamping of the aorta has been performed since the beginning of aortic surgery. However, the use of aortic balloons is also well known. These balloons are not only used in aortic surgery or during the remodelling of stent grafts but also in situations with heavy bleeding from the pelvis.<sup>10</sup> IABO has also been used electively on patients undergoing a Caesarean section due to placenta previa percreta.<sup>6</sup> However, fluoroscopy or CT has been regarded as necessary in the insertion of an occlusive balloon into the aorta from the femoral artery. In addition, most balloons demand introducers with diameters larger than 8 French. By using NuMED sizing balloons with diameters 25 mm or less, an 8 French introducer was sufficient to access the artery. A safe and easy sealing of the artery after removal of the introducers was also made possible by using the 8 French Angio-Seal (Minnetonka, MN, USA) device.

In one patient, the balloon inflation resulted in a tear of the wall of a very gracile aorta.

In five of these cases, the balloon was deflated after 10–15 min for a short time period to evaluate the status of the bleeding. In addition, balloon deflation allowed reperfusion of the occluded organs and the lower limbs to prevent formation of thrombus and reduce the risk of distal embolization, because the patients were not heparinized. In addition, we wanted to avoid further hypotension because reperfusion and flushing of ischaemic metabolites from the pelvis and the lower extremities may contribute

to this condition. The formation of a thrombus or distal embolization was not observed in any of the six patients; however, the sample size was too small to assess complications related to distal embolization.

In some patients, a temporary occlusion of the visceral arteries and the renal arteries might have taken place. However, this possibility was regarded as a minor problem relative to the ongoing and potentially life-threatening exsanguination. In three patients, partial deflation and retraction of the catheter to the aortic bifurcation was performed within 10 min of the primary balloon inflation. Nevertheless, the kidneys can withstand approximately 40 min of warm ischaemia without damage.<sup>11</sup>

In addition to the circulatory benefits achieved with this technique, both inspection and surgical management of the vaginal tears were easier due to a better overview of the operating field. An occluded aorta also gave the obstetricians time to do a thorough examination and to wait for the effects of drugs that were provided to induce contraction in the atonic uterus. If the patient was still bleeding after approximately 30 min, a hysterectomy or embolization was performed.

The use of expensive blood products may also be reduced by this method, especially if the method is used during an early phase of PPH. Nevertheless, we cannot rule out the probability that these patients could have been managed with traditional methods. However, we think this method is of value early in the process because of its relative simplicity and the fact that one can limit the use of blood products and the development of the deadly triad of hypothermia, acidosis and coagulopathy.

Stabilization of any patient with heavy bleeding in the abdomen, pelvis or the lower extremities with IABO may give doctors the additional time needed to perform a primary surgery or prepare an alternative treatment, such as embolization or a more controlled surgery. This may also be a good method for treating multitraumatized patients or for patients undergoing extensive surgeries, where heavy bleeding might be expected.

Due to the complications noted in case 6, the balloon was changed to a smaller 20 × 30 mm NuMED PTX-S (NuMED Canada Inc., Cornwall, ON, Canada) catheter. The diameter of the infrarenal aorta in young women seldom exceeds 20 mm. In addition, we set a maximum limit of 8 ml of saline that can be pumped into the balloon. We also recommend the use of a 20 ml syringe instead of a

smaller syringe, which makes it easier for the interventionalist to feel the resistance as the balloon hits the aortic wall during inflation. Successful use of this smaller balloon has been performed recently but is not referred to in this article.

With the method described in this article, six IRs were able to place an aortic occlusion catheter into the abdominal aorta without the use of fluoroscopy in six patients with life-threatening PPH. In hospitals without IRs on-call, we believe that anaesthesiologists can also perform this procedure if they are trained in US-guided access to the common femoral artery.

## Conclusion

This article describes the use of IABO without the use of fluoroscopy to halt potentially life-threatening PPH in six patients. The procedures resulted in reduced bleeding and acted as a bridge intervention that allowed for the eventual delivery of definitive treatment. We believe this method will contribute to a reduced mortality among patients with severe PPH.

*Conflict of interest:* There is no known conflict of interest.

## References

1. Sloan NL, Durocher J, Aldrich T, Blum J, Winikoff B. What measured blood loss tells us about postpartum bleeding: a systematic review. *BJOG* 2010; 117: 788–800.
2. Ahonen J, Stefanovic V, Lassila R. Management of postpartum haemorrhage. *Acta Anaesthesiol Scand* 2010; 54: 1164–78.
3. Hughes CW. Use of an intra-aortic balloon catheter tamponade for controlling intra-abdominal hemorrhage in man. *Surgery* 1954; 36: 65–8.
4. Hesse FG, Kletschka HD. Rupture of abdominal aortic aneurysm: control of hemorrhage by intraluminal balloon tamponade. *Ann Surg* 1962; 155: 320–2.
5. Robicsek F, Daugherty HK, Mullen DC. The elective use of balloon obstruction in aortic surgery. *Surgery* 1970; 68: 774–7.
6. Howard ER, Young AE. Control of aortic haemorrhage by balloon catheter. *BMJ* 1971; 3: 161.
7. Masamoto H, Uehara H, Gibo M, Okubo E, Sakumoto K, Aoki Y. Elective use of aortic balloon occlusion in cesarean hysterectomy for placenta previa percreta. *Gynecol Obstet Invest* 2009; 67: 92–5.
8. Harma M, Harma M, Kunt AS, Andac MH, Demir N. Balloon occlusion of the descending aorta in the treatment of severe post-partum haemorrhage. *Aust N Z J Obstet Gynaecol* 2004; 44: 170–1.
9. Miura F, Takada T, Ochiai T, Asano T, Kenmochi T, Amano H, Yoshida M. Aortic occlusion balloon catheter technique is useful for uncontrollable massive intraabdominal bleeding after hepato-pancreato-biliary surgery. *J Gastrointest Surg* 2006; 10: 519–22.

**E. Søvik et al.**

10. Martinelli T, Thony F, Decléty P, Sengel C, Broux C, Tonetti J, Payen JF, Ferretti G. Intra-aortic balloon occlusion to salvage patients with life-threatening hemorrhagic shocks from pelvic fractures. *J Trauma* 2010; 68: 942–8.
11. Godoy G, Ramanathan V, Kanofsky JA, O'Malley RL, Tareen BU, Taneja SS, Stifelman MD. Effect of warm ischemia time during laparoscopic partial nephrectomy on early postoperative glomerular filtration rate. *J Urol* 2009; 181: 2438–43.

Address:

*Edmund Søvik*

Department of Radiology

St. Olavs University Hospital

7006 Trondheim

Norway

e-mail: [edmund.sovik@stolav.no](mailto:edmund.sovik@stolav.no)